



## International Journal of Innovative Research in Computer and Communication Engineering

(An ISO 3297: 2007 Certified Organization)

Website: [www.ijirce.com](http://www.ijirce.com)

Vol. 5, Issue 6, June 2017

# Microaneurysms Detection Digitally Retinal fundus images Automatically

Amit Goswami, Vatsya Tiwari

M.Tech Scholar, Department of Computer Science, B.S.A College of Engineering & Technology, Mathura, India

Assistant Professor, Department of Computer Science, B.S.A College of Engineering & Technology,  
Mathura, India

**ABSTRACT:** Diabetic retinopathy is a complication of diabetes and a leading cause of blindness in the world. It occurs when diabetes damages the tiny blood vessels inside the retina. The main two types of diabetic retinopathy the first are non-proliferate diabetes retinopathy (NPDR) and second are proliferate diabetes retinopathy (PDR). Images analysis by trained individuals, which can be a very costly and time consuming task due to the large diabetic population. The increasing number of DR cases world-wide. Therefore, demands to the development of an automated detection system for reduce the work load of ophthalmologists in diagnosis the disease. This research proposed is developed computer based system for the automatically detection of diabetic retinopathy in the fundus images using Support vector classification (SVM) algorithm. The proposed methodology, using DIARETDB1 in which have total 89 images, achieves an accuracy of 95.38%, sensitivity of 94 % and a specificity of 94.7%.

**KEYWORDS:** Diabetic retinopathy, Image processing, screening, Microaneurysm, Fundus image analysis.

### I. INTRODUCTION

Diabetes is a disorder of sugar metabolism caused by an impairment of insulin raised levels of glucose in the blood. High levels of glucose in the blood can damage the vessels that supply blood to vital organs. Diabetic Retinopathy (DR) is the resultant disorder affecting the retinal vasculature, leading to progressive retinal damage that can loss to vision and can occur blindness [2]. DR is recognized as the leading cause of blindness in the working-age population [3]. The problem is increasing in its scale, with diabetes having been identified as a significant growing global public health problem [4]; in fact in the United Kingdom three million people are estimated to have diabetes in future is may be expected to double in the next 15-30 years. Diabetic Patients are required to attend regular eye screening needed to appointments in which DR, a retinal disorder, can be assessed. From these appointments digital retinal images are captured, and these then undergo various stages of analysis by trained individuals. This can be a very time consuming and costly task due to the large number of diabetic patients. Therefore this is a field that would greatly benefit from the introduction of automated detection systems [1]. Not only would its implementation be more cost effective, but the screening program and the National Health organization (NHO) would benefit in numerous other ways. Results would be produced more quickly, thus allowing patients to receive results as soon as possible hence minimizing anxiety and also ensuring referrals to the hospital eye service. Another benefit arises from the fact that human graders are subjective and can also become fatigued, whereas an automated system would provide consistent objective results. In medical imaging the quality of the image acquisition and the image interpretation determines the accuracy of diagnosis. Desktop have a huge impact on the of medical images acquisition. They perform multipronged functions like controlling imaging, performing reconstruction, post-processing of the image data and storing the scans. In contrast, the role of computers in the interpretation of medical images has so far been limited. This paper describes components an automatic system that can aid in the detection of diabetic retinopathy. DR is an eye disease and its causes vision loss, if left undiagnosed at the initial stage. In the world number of diabetes affected people is increasing, the need to increase automated detection methods for diabetic retinopathy. To automatically detect diabetic retinopathy, a computer has to interpret and analyze digital images of the retina.

# International Journal of Innovative Research in Computer and Communication Engineering

(An ISO 3297: 2007 Certified Organization)

Website: [www.ijircce.com](http://www.ijircce.com)

Vol. 5, Issue 6, June 2017

In this work developed to assist ophthalmologist's diagnosis by providing second opinion and also functions as an automatic tool for the mass screening of diabetic retinopathy. Colour fundus images are used by ophthalmologists to study eye diseases like diabetic retinopathy. Extraction of the normal features like optic disk, fovea and blood vessels; and abnormal features like exudates, cottonwool spots, microaneurysms and hemorrhages from colour fundus images are used in fundus image analysis system for comprehensive analysis and grading of diabetic retinopathy[5]. This CAD system also provides the spatial distribution of abnormalities based on fovea such that an ophthalmologist can make a detailed diagnosis. This introductory Chapter presents some background information on the anatomy of the eye, diabetic retinopathy, and diabetic retinopathy screening [6].

**Diabetic Retinopathy:** Diabetic retinopathy is the prime cause of vision loss amongst the working age population of the developing and the developed countries. Diabetic patients are 25 times more probable to become blind than non-diabetic patients [1]. Diabetic retinopathy is a complication of diabetes to the retina. Both the forms of diabetes i.e. diabetes mellitus and diabetes insipidous, leads to diabetic retinopathy eventually after some time. It is a very asymptomatic disease in the early stages and it could lead to permanent vision loss.



Fig.1. (a) non diabetic retinopathy Vision (b) With Retinopathy vision

Their number will increase. Hemorrhages look either as small red dots or blots identical to microaneurysms or as larger flame-shaped hemorrhages. The vessels besides leaking blood also cause the leakage of lipids and proteins paving way for the appearance of small bright dots called exudates (Fig. 1. (b)). They are seen on the retina as typical bright, reflective white or cream coloured lesions that indicate increased blood vessel permeability and an allied risk of retinal edema. If this takes place on the macula region vision may be lost.

## II. RELATED WORK

This chapter provides the details related to basics of medical domain, especially ophthalmology. The main focus of this literature review has been to study in detail the various image processing techniques involved in the field of retinal image analysis. This chapter also presents a detail literature survey of existing methods on the automatic detection of anatomical structures in retina and current scenario of automatic diagnostic systems. The extraction of features has also been documented in detail. The research field of retinal image analysis has attracted a lot of interest in the last couple of decades, with the automated detection of Diabetic Retinopathy (DR) having received a considerable share of this interest. Revolutionary detection is also an area that has received significant interest. Landmarks consist of blood vessels, the optic disc and the fovea. This section will start with a brief review of the automated segmentation of blood vessels. Most DR detection methodologies use it as a requirement before identifying pathological entities

**Blood Vessel Segmentation :** Several studies were carried out on the segmentation of blood vessels in generally some of the main attributes of vessels that are utilized in segmentation methods are their deep red colour, their contrast with the background, and their gradient at vessel edges. however only a small number of them were associated to retinal blood vessels. In order to review the methods proposed to segment vessels in retinal images, seven classes of methods



# International Journal of Innovative Research in Computer and Communication Engineering

(An ISO 3297: 2007 Certified Organization)

Website: [www.ijircce.com](http://www.ijircce.com)

Vol. 5, Issue 6, June 2017

have been considered: matched filters, vessel tracking, morphological processing, region growing, multiscale, supervised and adaptive thresholding approaches.

**Matched Filters:** Matched filters are based on a correlation measure between the expected shape sought for and the measured signal. The algorithm presented by Chaudhuri et al. [1] was based on directional 2D matched filter. To enhance retinal vasculature a 2D matched filter kernel was designed to convolve with the original fundus image. The kernel was rotated into either eight or twelve orientations to fit into blood vessels of various configurations. A number of kernel shapes have been investigated. Gaussian kernels were used in [1-3]. Kernels based on lines [4] and partial Gaussian kernels were also used [5]. A number of approaches were also proposed to identify true blood vessels from the matched filter response. A region based threshold probe was applied to the response of matched filter to segment the vessel network [3]. An amplitude modified second order differential Gaussian filter was proposed by [6] to detect the vessel network at different scales that match their widths. This was achieved by changing the amplitude, so that responses can be merged over scales. Local entropy based thresholding was proposed by Maher et al. [7].

**Morphological Processing:** To segment the blood vessels in a retinal image, mathematical morphology can be used since the vessels were the patterns that exhibit morphological properties. Then returning to the original pre-processed image, vessel enhancement was performed separately at different scales by using a modified top hat operator (morphological operator) with a disc structural element of increasing size used to enhance vessels with different widths, such as connectivity, linearity and curvature of vessels varying smoothly along the crest line. But background patterns also fit to such a morphological description. In order to discriminate blood vessels from other similar structures, cross-curvature evolution and linear filtering were employed by Klein et al. [8]. A two step method was applied to segment vasculature by Purty et al. [9]. Firstly, mathematical morphology filtering coupled with curvature evolution was utilized to enhance the blood vessels in fundus images.

### III. DIGITAL IMAGE DATABASE AND PREPROCESSING

Fundus imaging has an important role in diabetes monitoring since occurrences of retinal abnormalities are common and consequences serious. However, since the eye fundus seems to be sensitive to vascular diseases, fundus imaging is considered as a candidate for non-invasive screening of diabetes. The success rate of screening depends on accurate fundus image capturing and especially on accurate and reliable image processing algorithms for detecting the abnormalities. Various algorithms have been proposed by many research groups for this purpose. However, it is impossible to judge the accuracy and reliability of the approaches because of the lack of commonly accepted and representative fundus image database and evaluation protocol. One publicly retinal databases available called DIARETDB1 standard database is used for testing exudate detection method. The details of these databases are as follows.

**Diaretdb1 Database :** The database consists of 89 colour fundus images of which 84 contain at least mild non-proliferative signs of the diabetic retinopathy (see Figure 3.), and five are considered as normal which do not contain any signs of the diabetic retinopathy according to all the experts participated in the evaluation. Images were captured with the same 50 degree field-of-view digital fundus camera with varying imaging controlled by the system in the Kuopio university hospital, Finland. The image ground truth provided along with the database is based on expert selected findings related to the diabetic retinopathy and normal fundus structures. Special software was used to inspect the fundus images and annotate the findings as hard exudates, hemorrhages and microaneurysms.

# International Journal of Innovative Research in Computer and Communication Engineering

(An ISO 3297: 2007 Certified Organization)

Website: [www.ijircce.com](http://www.ijircce.com)

Vol. 5, Issue 6, June 2017

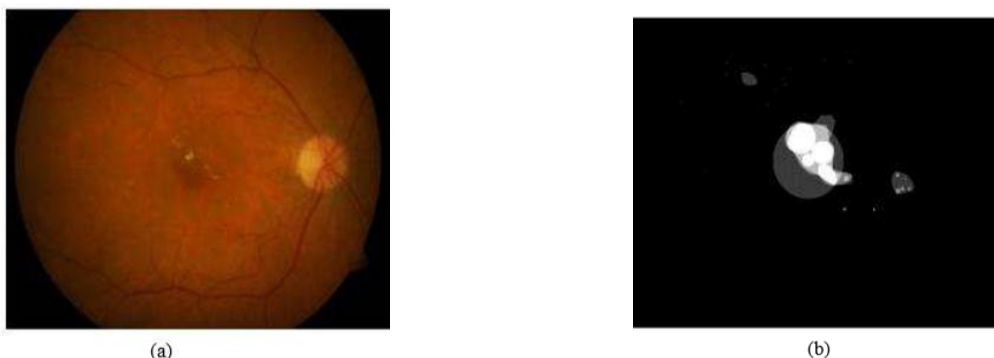


Fig.2. (a) Example of abnormal fundus image from DIARETDB1 database (b) Ground truth of hard exudates.

**Pre-processing:** Patient movement, poor focus, bad positioning, reflections, inadequate illumination can cause a significant proportion of images to be of such poor quality as to interfere with analysis. In the retinal images there can be variations caused by the factors including differences in cameras, illumination, acquisition angle and retinal pigmentation. Pre-processing is to reduce this effect by enhancing the contrast and normalizing the mean intensity. The objective of preprocessing is to attenuate the noise, to improve the contrast and to correct the non-uniform illumination. The colour retinal images taken at screening programs are often poorly contrasted and contain artifacts. A local contrast enhancement method [12] and Polynomial contrast enhancement is applied to the intensity image to improve both the contrast of bright lesions and the overall colour saturation of the retinal image. There can also be difference in the colour of the fundus due to retinal pigmentation among different patients. These images are preprocessed before they can be subjected to anatomical and pathological structure detection.

## IV. EXPERIMENTAL RESULTS AND DISCUSSION

Diabetic retinopathy is one of the prime causes of vision loss and blindness amongst the people of developing and developed world and present in 30% of diabetic population [1]. Blindness from diabetic retinopathy can be prevented but needs regular eye checks and control of blood sugar levels. Microaneurysms such as Dark lesions and hemorrhages and bright lesions such as hard exudates and cottonwool spots are the visible signs of diabetic retinopathy. Microaneurysms also known as red lesions are the first clinically observable lesions indicating diabetic retinopathy. Therefore, their detection is very important for a diabetic retinopathy screening system. The major challenges in dark lesion detection are: Segmentation of small Dark lesions in the regions of low image contrast. The presence of bright pathologies. Normally bright lesions have sharp edges. These sharp edges can be detected as false positives in the later stages. The principal objective in this chapter is to develop a new method that can identify fundus images consisting microaneurysms and hemorrhages with a very high sensitivity by segmenting all the possible microaneurysms, while avoiding false responses near bright pathologies and other non-dark lesion structures. The proposed dark lesion detection method comprises of three steps. First, the green channel of each colour retinal image is extracted and is preprocessed using polynomial contrast enhancement. Next, the candidate objects representing microaneurysms are segmented.

**Support Vector Machine:** SVM are a set of supervised learning tools applied for data classification and regression. SVM model maps the training samples that are the points in features space into different categories which are clearly separated with the widest gap in between them. The testing samples are mapped to the same feature space and classified as belonging to any of the classes. SVM constructs an optimal hyper plane that would maximize the margin of separation between the classes. The feature vectors that lie close to the margin are called the support vectors. Figure 4. Depicts the SVM classifier with the optimum hyperplane. A binary SVM finds an optimum hyper plane which separates the feature vectors of the two classes with largest margin from the hyper plane.

**Candidate Microaneurysm Detection System:** Microaneurysms detection is very important, because these structures constitute the earliest recognizable feature of DR. Here, the potential microaneurysms are segmented from the preprocessed images. The objects thus segmented are called candidate objects.

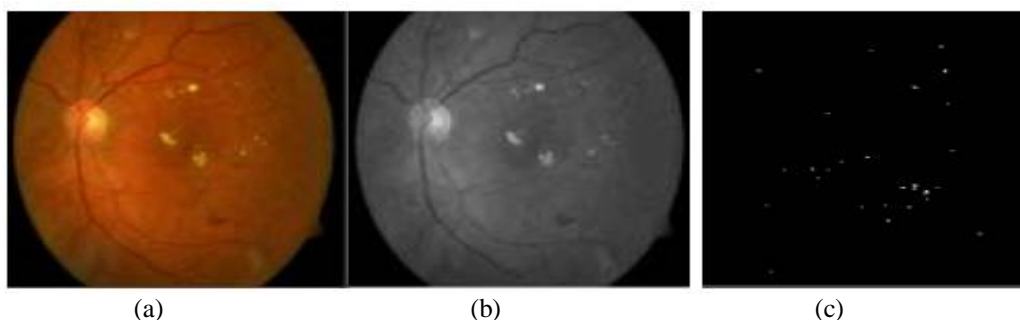
# International Journal of Innovative Research in Computer and Communication Engineering

(An ISO 3297: 2007 Certified Organization)

Website: [www.ijircce.com](http://www.ijircce.com)

Vol. 5, Issue 6, June 2017

**Mathematical Morphology Based Method:** After the image is preprocessed, the candidate microaneurysms are segmented by separating circular, non-connected microaneurysms from the blood vessels. Morphological top-hat transformation is applied for this purpose. The top-hat transformation is based on morphologically opening an image using a linear structuring element. Twelve rotated structuring elements are applied with radial resolution of the structuring element length should be chosen such that it must be larger than the largest microaneurysms present in the set.



**Fig.4 (a) Microaneurysm on Colour Fundus Image (b) Micro-aneurysms on Colour Fundus Image (c) Detected Microaneurysms using Morphology Based Method.**

The drawback of candidate extraction technique based on mathematical morphology is that any exudates that is bigger than the linear structuring element cannot be identified. If the length of the structuring element is increased to extract larger objects, then more spurious candidate exudates objects will be detected on blood vessels as the segmentation of blood vessels deteriorates. A pixel classification based method can be used to eliminate this drawback. The proposed detection methods are tested and evaluated on DIARETDB1, a publicly available database of colored fundus images and corresponding ground truth images. Table 1: Performance of proposed method for hard exudates detection Database Total images Nonmicroaneurysm images No. of images with microaneurysms Sensitivity (%) Specificity (%) Diaretdb1 89 32 57 94% 94.7%

Lesion based evaluation and image based evaluation are employed to measure the accuracy of the proposed detection method at the pixel level. In example the green component, of the RGB fundus image, was chosen to obtain the microaneurysms. Similar to the exudates detection algorithm, first the prominent structures within retina images, Such as blood vessel tree and optic disc are to be removed. After that a sophisticated sequence of image processing algorithms was used to determine the areas within the fundus images to get microaneurysms.

## V. CONCLUSION

In this paper an automated method to detect microaneurysm in digital fundus images. A new candidate microaneurysm detection scheme based on matched filtering and local relative entropy is proposed. The performance of this microaneurysm detection method is compared with mathematical morphology based microaneurysm detection method. A proposed detection scheme that combines detection methods is tested as well. The results of the method on a per image basis show that the proposed detection scheme achieved an accuracy of 95.38%, sensitivity of 94% combined with 94.7% specificity.

## REFERENCES

- [1]. "Visual problems in the US data analysis definition, data sources, detailed data tables, analysis, interpretation. New York," National society to prevent blindness, 1980, pp.1-46.
- [2]. R. Klein, B. Klein, S. Moss, M. Davis, and D. DeMets, "The Wisconsin Epidemiologic Study of Diabetic Retinopathy. Prevalence and Risk of Diabetic Retinopathy when Age at Diagnosis is Less Than 30 Years" Archives of Ophthalmology, vol. 102, no. 4, 1984, pp. 520-526.
- [3]. R. Klein, B. Klein, S. Moss, M. Davis, and D. DeMets, "The Wisconsin Epidemiologic Study of Diabetic Retinopathy. Prevalence and Risk of Diabetic Retinopathy when Age at Diagnosis is 30 or more years." Archives of Ophthalmology, vol. 102, no. 4, 1984, pp. 527-532.





ISSN(Online): 2320-9801  
ISSN (Print): 2320-9798

# International Journal of Innovative Research in Computer and Communication Engineering

(An ISO 3297: 2007 Certified Organization)

Website: [www.ijircce.com](http://www.ijircce.com)

Vol. 5, Issue 6, June 2017

- [4]. Raju Maher, Sangramsing Kayte, Dnyaneshwar Panchal, Pankaj Sathe, Sandip Meldhe, "A Decision Support System for Automatic Screening of Non-proliferative Diabetic Retinopathy" International Journal of Emerging Research in Management and Technology, Volume-4, Issue-10, October-2015.
- [5]. J. Kinyoun, F. Barton, M. Fisher, L. Hubbard, L. Aiello, and F. Ferris, "Detection of Diabetic Macular Edema, Ophthalmoscopy versus Photography – Early Treatment Diabetic Retinopathy Study Report Number – 5, the ETDRS Research Group." Ophthalmology, vol. 96, 1989, pp. 746–750.
- [6]. Raju Sahebrao Maher, Sangramsing Kayte, Dnyaneshwar Panchal and Suvarnsing G. Bhable "Automatic diagnosis of diabetic retinopathy microaneurysm from low contrast retinal images using mathematical morphology methods", International Journal of Computer Applications, Volume 130 – No.6, November 2015.
- [7]. Raju Maher, Sangramsing Kayte, Suvarnsing Bhable, Jaypalsing Kayte, "Automated Detection of Microaneurysm, Hard Exudates, and Cotton Wool Spots in Retinal fundus Images", IOSR Journal of Computer Engineering, Volume 17, Issue 6, Ver. I (Nov – Dec. 2015), PP 152-156.
- [8]. R. Klein, B. Klein, S. Moss, M. Davis, and D. DeMets, "The Wisconsin Epidemiologic Study of Diabetic Retinopathy. Prevalence and Risk of Diabetic Retinopathy when Age at Diagnosis is 30 or more years." Archives of Ophthalmology, vol. 102, no. 4, 1984, pp. 527–532.
- [9]. A.J.Purty, D.R.Vedapriya, J.Bazroy, S.Gupta, J.Charian, M.Vishwanathan, "Prevalence of diagnosed diabetes in an urban area of Puducherry, India: Time for preventive action," International Journal on Diabetes in Developing Countries, vol.29, 2009, pp. 6-11.
- [10]. J. Kinyoun, F. Barton, M. Fisher, L. Hubbard, L. Aiello, and F. Ferris, "Detection of Diabetic Macular Edema, Ophthalmoscopy versus Photography – Early Treatment Diabetic Retinopathy Study Report Number – 5, the ETDRS Research Group." Ophthalmology, vol. 96, 1989, pp. 746–750.
- [11]. Early Treatment Diabetic Retinopathy Study Research Group, "Early Photocoagulation for Diabetic Retinopathy: ETDRS report 9", Ophthalmology, vol. 98, 1991, pp. 766–785.
- [12]. G. Bresnick, D. Mukamel, J. Dickinson, and D. Cole, "A Screening Approach to the Surveillance of Patients with Diabetes for the Presence of Vision-Threatening Retinopathy", Ophthalmology, vol. 107, no. 1, 2000, pp. 19–24.

## BIOGRAPHY

**Amit Goswami** is M.Tech Scholar in the Computer Science Department, College B.S.A College of Engineering & Technology, Dr. A P J Abdul Kalam Technical University Lucknow, Uttar Pradesh. His research interests are in Computer Graphics, image processing, Algorithms, web designing etc.